



PATIENT

Cleo Gray

SPECIES

Feline

BREED

DMH

SEX

Female Spayed

AGE

4 years

WEIGHT

5.14

INTERPRETED BY

Maggie Machen Lamy,
DVM, DACVIM
(Cardiology)

IMAGING PERFORMED BY

Alastair Westcott,
DVM

HOSPITAL NAME

Alastair Westcott,
DVM

REFERRING VET

Dr. Westcott

INVOICE

22862

DATE

3/1/22

PRESENTING CLINICAL SIGNS

History: Young cat, recently adopted. Grade IV/VI systolic murmur noted.

-Abnormal PE/Chem/CBC/UA Results: Abnormal ProBNP. Impression of mild cardiomegaly and an approximate "valentine" heart shape on radiographs.

ECHOCARDIOGRAM FINDINGS

2D, m-mode, color flow and doppler imaging is available. The left ventricular wall is asymmetric with severe septal and mild posterior wall hypertrophy. There is a mildly hyperechoic endocardium consistent with fibrosis and ventricular remodeling. Mild papillary muscle hypertrophy. The right ventricle is subjectively normal in size and morphology. There is borderline left atrial enlargement present. No right atrial enlargement present. Normal RVOT velocity. The anterior leaflet of the MV is mildly thickened and elongated. There is systolic anterior motion (SAM) of the mitral valve present, with an elevated LVOT velocity (not captured on Doppler). There is moderate eccentric mitral regurgitation present secondary to SAM. No other obvious valvular regurgitation is present. There is no pericardial effusion noted. No pleural effusion appreciated.

CARDIAC CHART

FELINE CARDIAC PARAMETERS	BODY WEIGHT	HR (BPM)	IVSd (cm) (Moise, Pipers)	LVIDd (cm) (Moise, Pipers)	LVWd (cm) (Moise, Pipers)	FS (%)	EF (%)
NORMAL PARAMETER	-----	150-240	0.35-0.55	<2 (mean 1.5)	3.5-0.55	35-67	80-100
PATIENT	5.14	NM	0.8	1.1	0.67	53	88
FELINE CARDIAC PARAMETERS	LA/AO (Boon)	LA/AO HEART BASE (Swe) (Abbott)	LA 2D short axis Base view (cm) (Abbott)		LVOT VEL (m/s)	RVOT VEL (m/s)	E max (m/s)
NORMAL	<1.5	<1.3	<1.2		<1.6	<1.3	<0.9
PATIENT	NM	1.4	1.3		NM	1.8	NM
<p><i>*Note: All measurements based upon multi-modal images and methods. An average value is reported.</i> Adapted from June Boon, Veterinary Echocardiography, 1998 Abbott J & MacLean H JVIM 2006;20: 111-119, Moise et al. Am J Vet Res 47:1476, 1986. Pipers et al. Am J Vet Res 40:882, 1979.</p>							

INTERPRETATION OF THE FINDINGS & FURTHER RECOMMENDATIONS

The presumptive diagnosis and cause of the murmur is mitral valve dysplasia leading to LV hypertrophy and an obstructive LVOT flow pattern. A primary hypertrophic component is also possible as a concurrent issue, particularly given only a mildly abnormal mitral valve. There is only borderline left atrial dilation indicating the risk of spontaneous CHF and/or a thrombotic event is currently low. No additional issues are identified.

In cases of solely primary MV dysplasia use of atenolol can lead to improvement in the degree of obstruction and hypertrophy. Given today's findings it is reasonable to initiate at this time as below. Monitor at home for any respiratory signs or evidence of blood clot events (neurologic change, paralysis, etc.).

Long term prognosis is guarded given the highly variable nature of asymptomatic feline heart disease. Many cats will remain asymptomatic until mid-life or beyond, while others develop CHF within the first years. Close monitoring for response/improvement with atenolol, progression of LA dilation/LVH in the future will help determine long term prognosis.



PATIENT

Cleo Gray

Anesthetic risk is considered mildly elevated, with risk for fluid overload, spontaneous CHF, hypotension, etc. Judicious IV fluid rates are advised to avoid fluid overload. Drugs that stimulate heart rate should be avoided unless clinically necessary (glycopyrrolate, atropine). Avoid ketamine, telazol, acepromazine and Dexdomitor.

SPECIES

Feline

PLAN

Screening BP. Administer titrating dose of atenolol: 25mg tablets; Give ¼ tab once daily. Recheck heart rate in 1-2 weeks with target stressed rate of 140-160bpm 12-24 hours post-administration. Increase as needed until target reached. Screening blood pressure is recommended.

BREED

DMH

SEX

Female Spayed

Recommend recheck echocardiogram in 6 months to assess for progression and response to therapy, sooner if clinical issues arise.

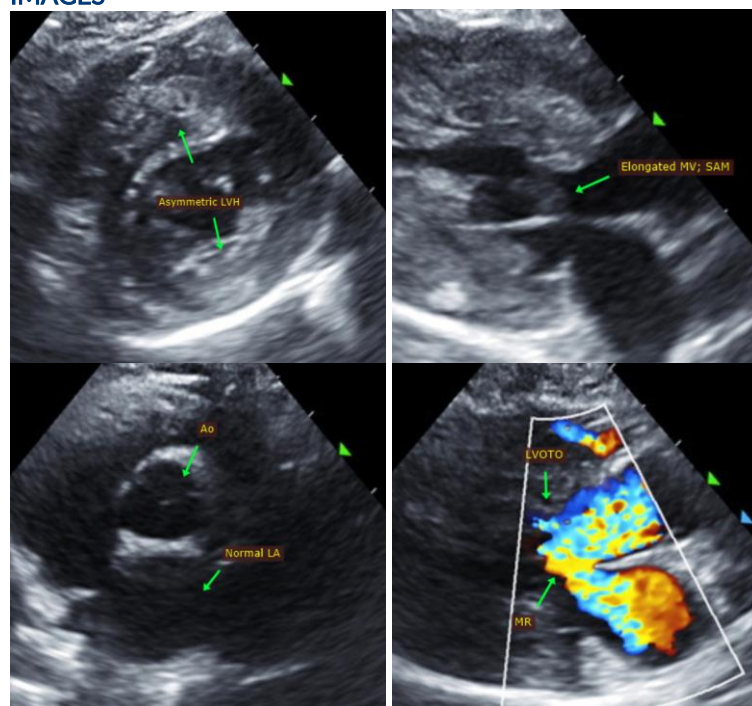
AGE

4 years

IMAGES

WEIGHT

5.14



INTERPRETED BY

Maggie Machen Lamy,
DVM, DACVIM
(Cardiology)

IMAGING PERFORMED BY

Alastair Westcott,
DVM

HOSPITAL NAME

Alastair Westcott,
DVM

REFERRING VET

Dr. Westcott

The information and recommendations provided are based on the images presented by the referring veterinarian. No evaluation can be communicated regarding pathology that was not visible in the image/video clips provided.

INVOICE

22862

Thank you for this referral. This report was generated using transcription software, and minor dictation errors may be present. If the clinical or image interpretation does not parallel your findings or if I can be of any further assistance, please contact me.

DATE

3/1/22

Maggie Machen Lamy, DVM
Diplomate of the American College of Veterinary Internal Medicine (Cardiology)
info@sonopath.com